


# D-Sign on Ultrasound

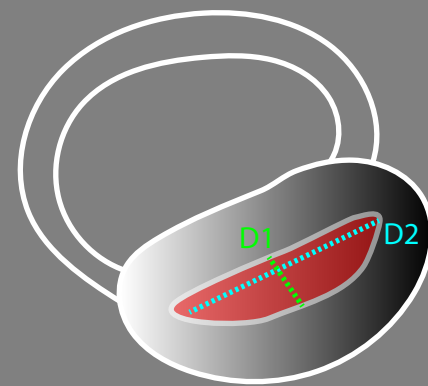
## Right Ventricular Pressure vs Volume Overload

Eccentricity  
Index (EI)

$$EI = D2/D1$$



Normal  
 $EI \leq 1$



RV Overload  
"D Sign"  
 $EI > 1$

Normal

Pressure Overload

Volume Overload

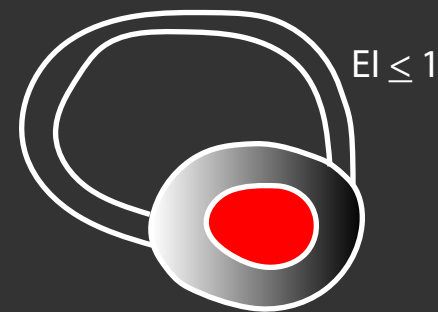
Systole



$EI \leq 1$



$EI > 1$   
D Sign



$EI \leq 1$

Diastole



$EI \leq 1$



$EI > 1$   
D Sign



$EI > 1$   
D Sign