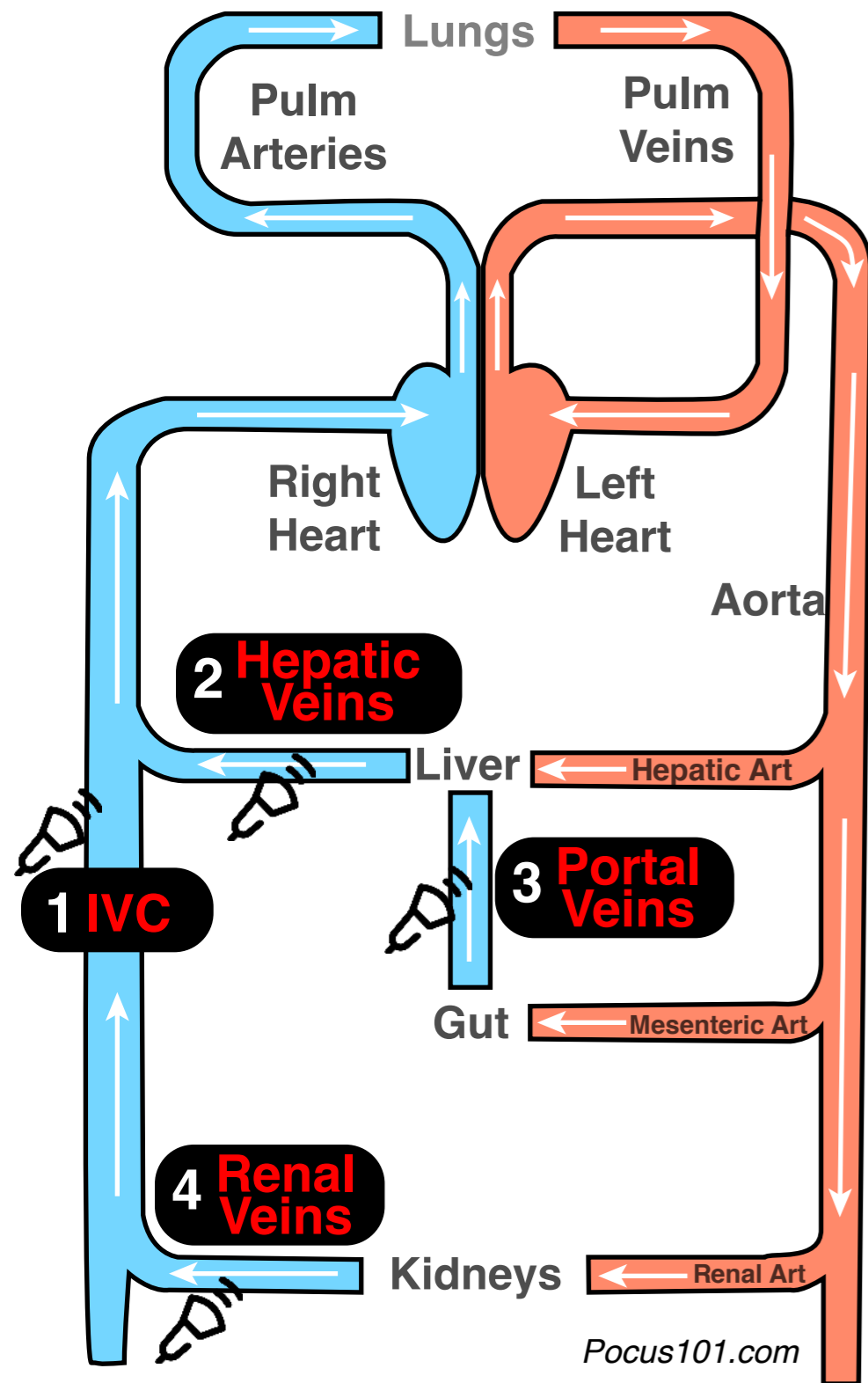
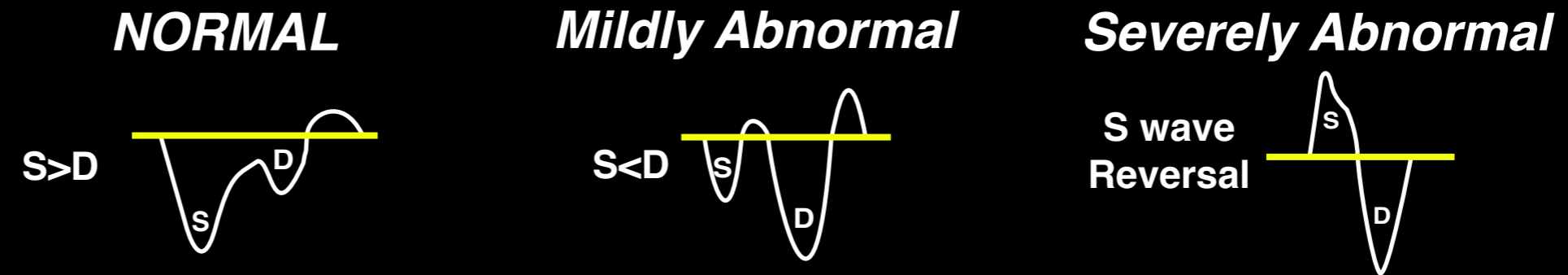


Venous Excess Ultrasound VExUS

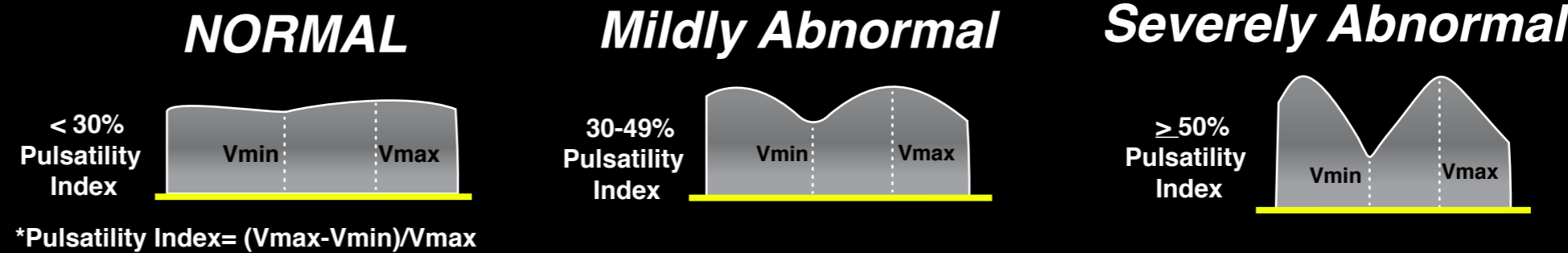


Step 1: IVC Diameter: If $\geq 2\text{cm}$, proceed to step 2

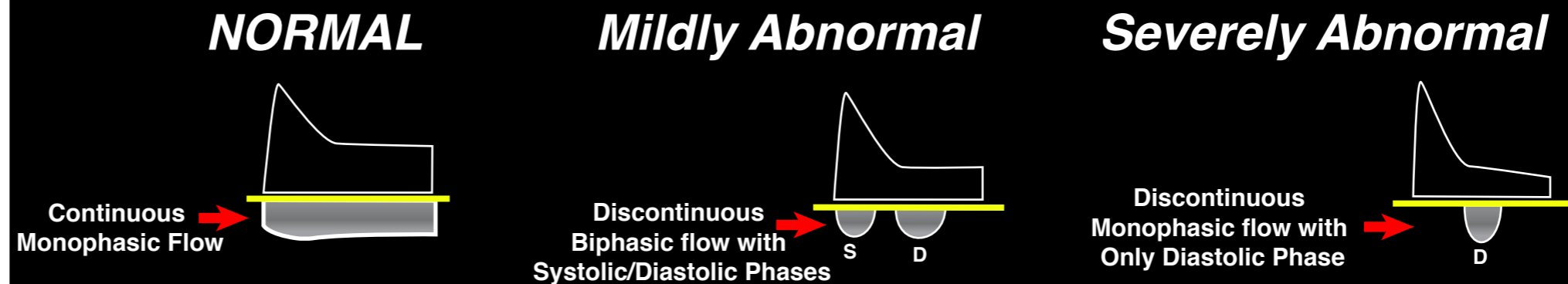
Step 2: Hepatic Vein Doppler



Step 3: Portal Vein Doppler



Step 4: Renal Vein Doppler



Interpretation

Grade 0
(no congestion)

IVC $< 2\text{cm}$

Grade 1
(Mild congestion)

IVC $\geq 2\text{cm}$
and any combo
of Normal or
Mildly Abnl
Patterns

Grade 2
(Moderate congestion)

IVC $\geq 2\text{cm}$
and
ONE Severely Abnl
Pattern

Grade 3
(Severe congestion)

IVC $\geq 2\text{cm}$
and
 ≥ 2 Severely Abnl
Patterns