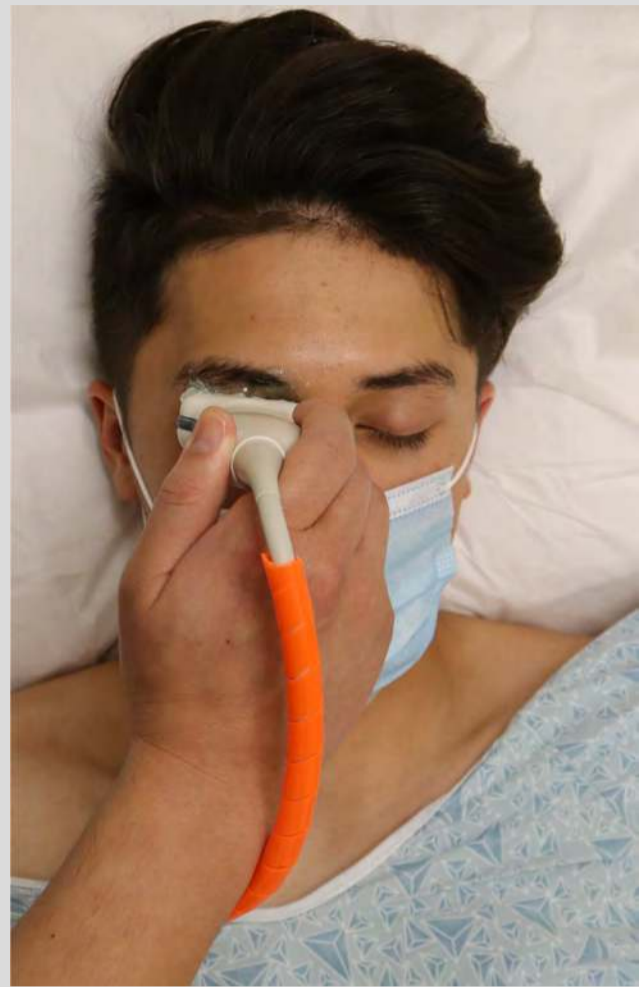
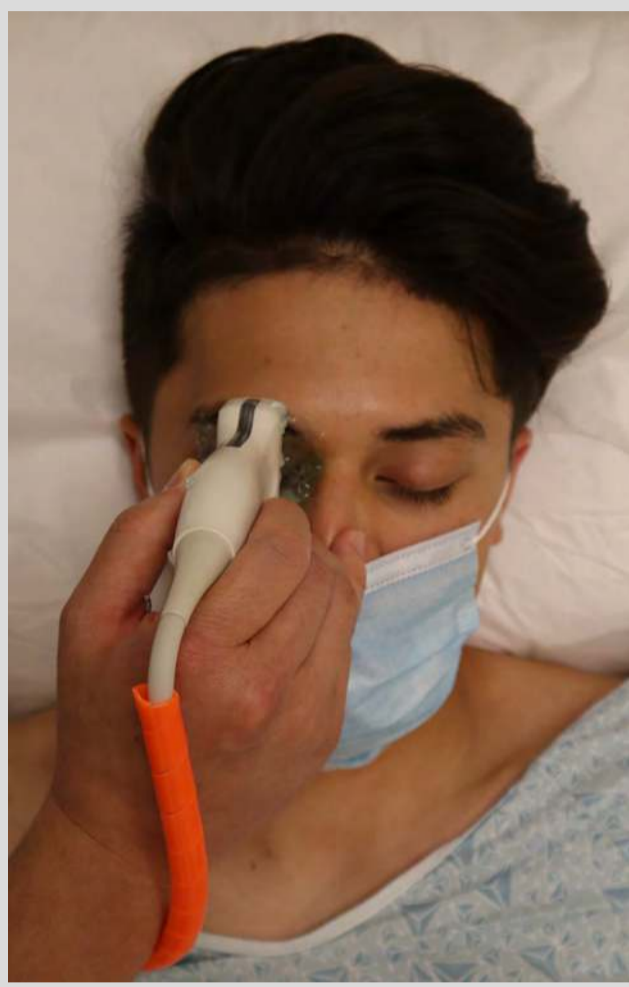
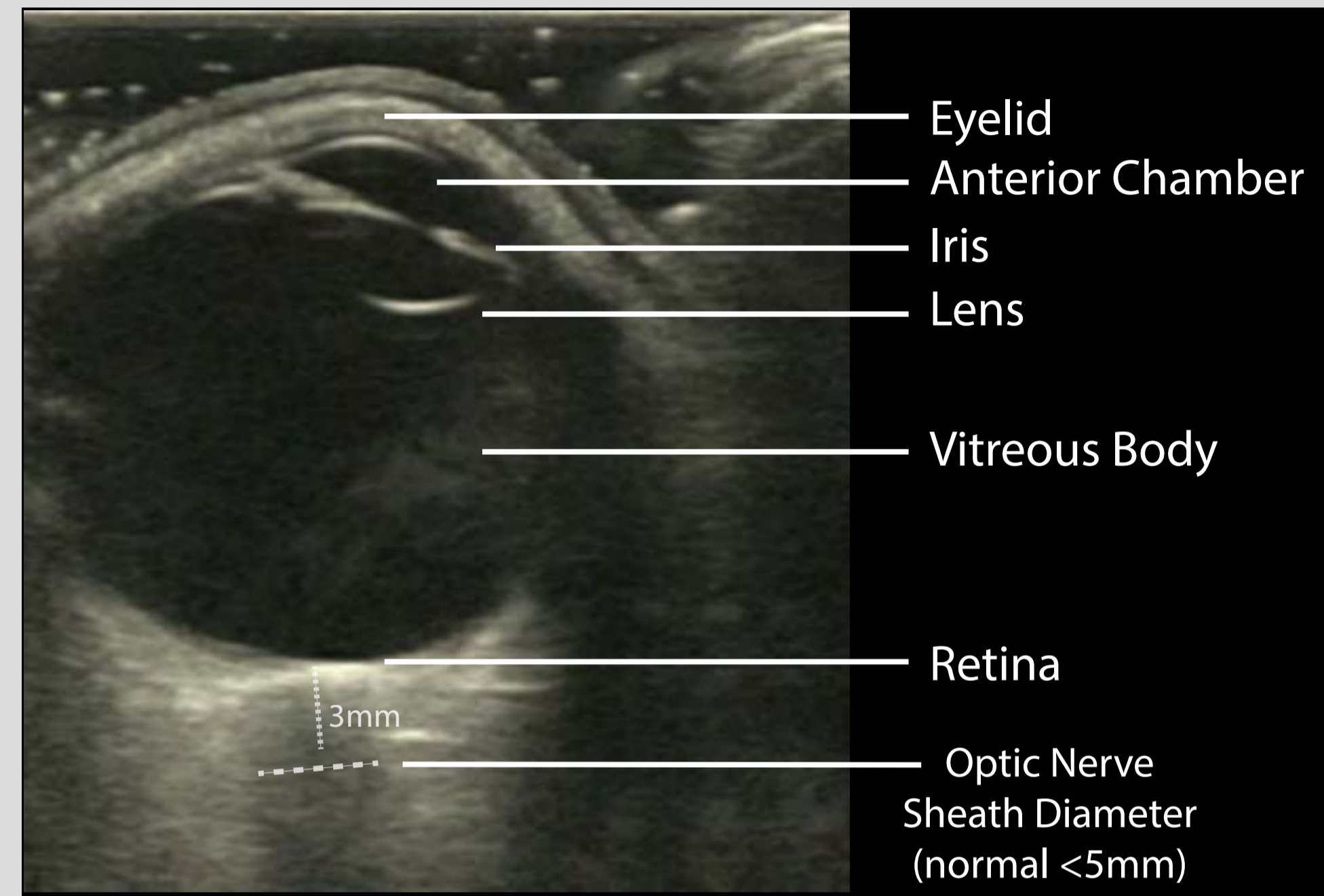
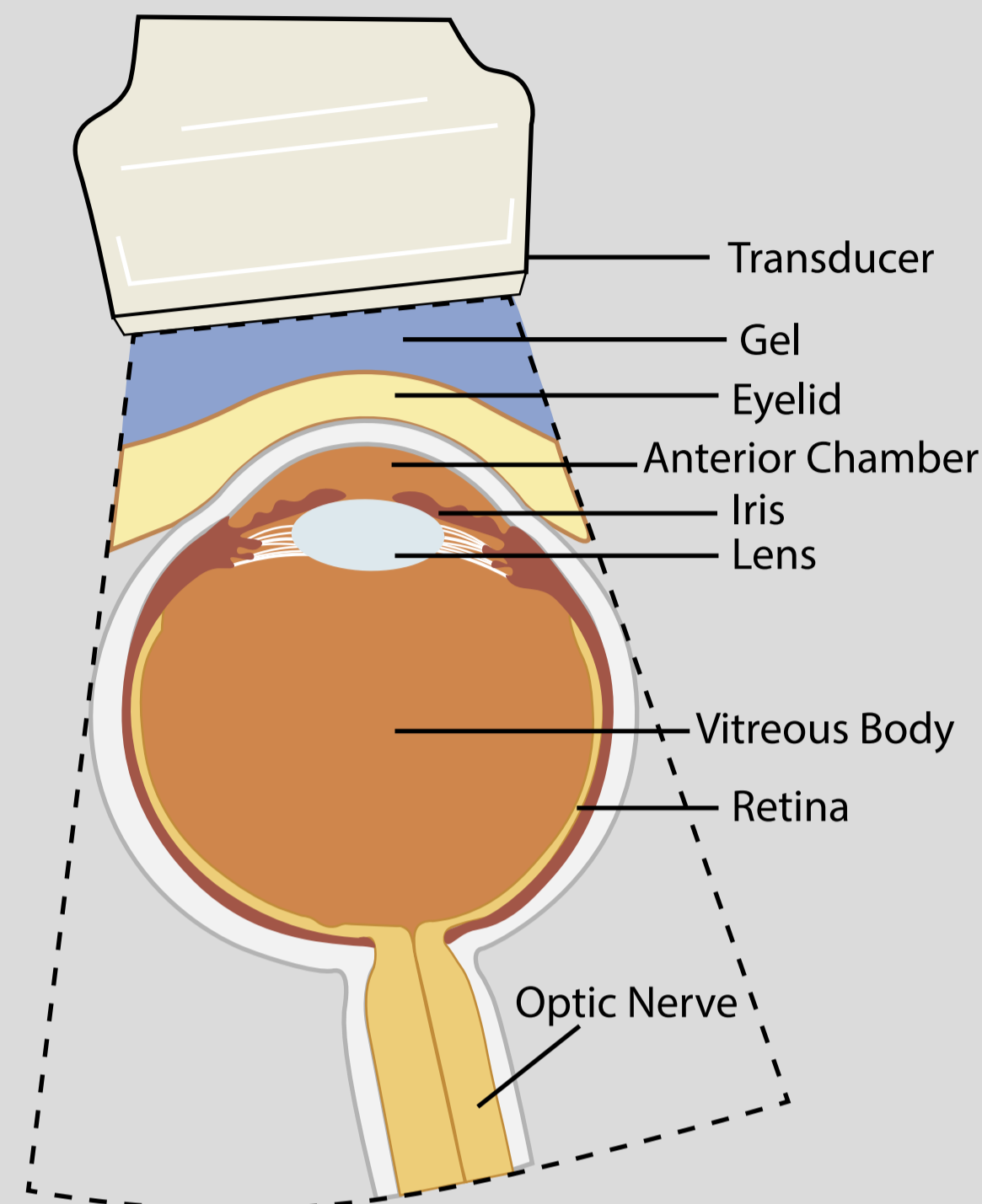
Ocular Ultrasound Pocket Card



Probe: Linear
Mode: Ocular
Transverse View



Probe: Linear
Mode: Ocular
Sagittal View



Painless Vision Loss

<p>Retinal Detachment</p> <p>Attached to Optic Nerve</p>	<p>Posterior Vitreous Detachment</p>	<p>Vitreous Hemorrhage</p> <p>Washing Machine Sign</p>	<p>Central Retinal Artery Occlusion</p>
---	---	---	--

Elevated Intracranial Pressure

<p>Intracranial Hemorrhage</p> <p>+ 3 mm x: >5 mm</p> <p>ONSD Dilatation</p>	<p>Pseudotumor Cerebri (Idiopathic Intracranial Hypertension)</p> <p>Optic Disc Elevation</p> <p>+ 3 mm x: >5 mm</p> <p>ONSD Dilatation</p>
--	---

Traumatic Vision Loss

<p>Retinal Detachment</p> <p>Attached to Optic Nerve</p>	<p>Intraocular Foreign Body</p> <p>Foreign Body</p>	<p>Globe Rupture</p> <p>Flattening of Anterior Chamber</p> <p>Buckling of Sclera</p> <p>Decreased Globe Size</p>	<p>Lens Dislocation</p>	<p>Retrobulbar Hemorrhage</p> <p>Guitar Pick Sign</p> <p>Hypoechoic Blood</p>	<p>Periorbital Edema</p> <p>Swelling of Eyelid</p>
---	--	---	--------------------------------	--	---