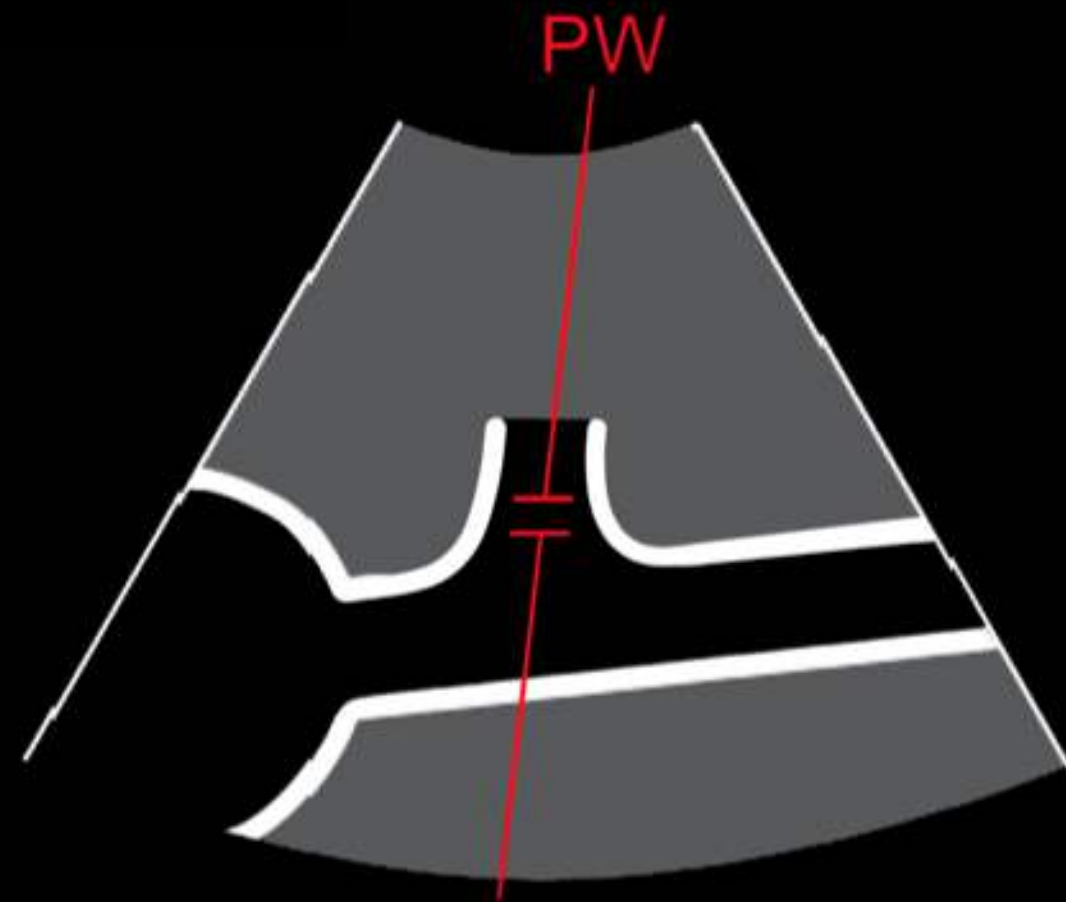
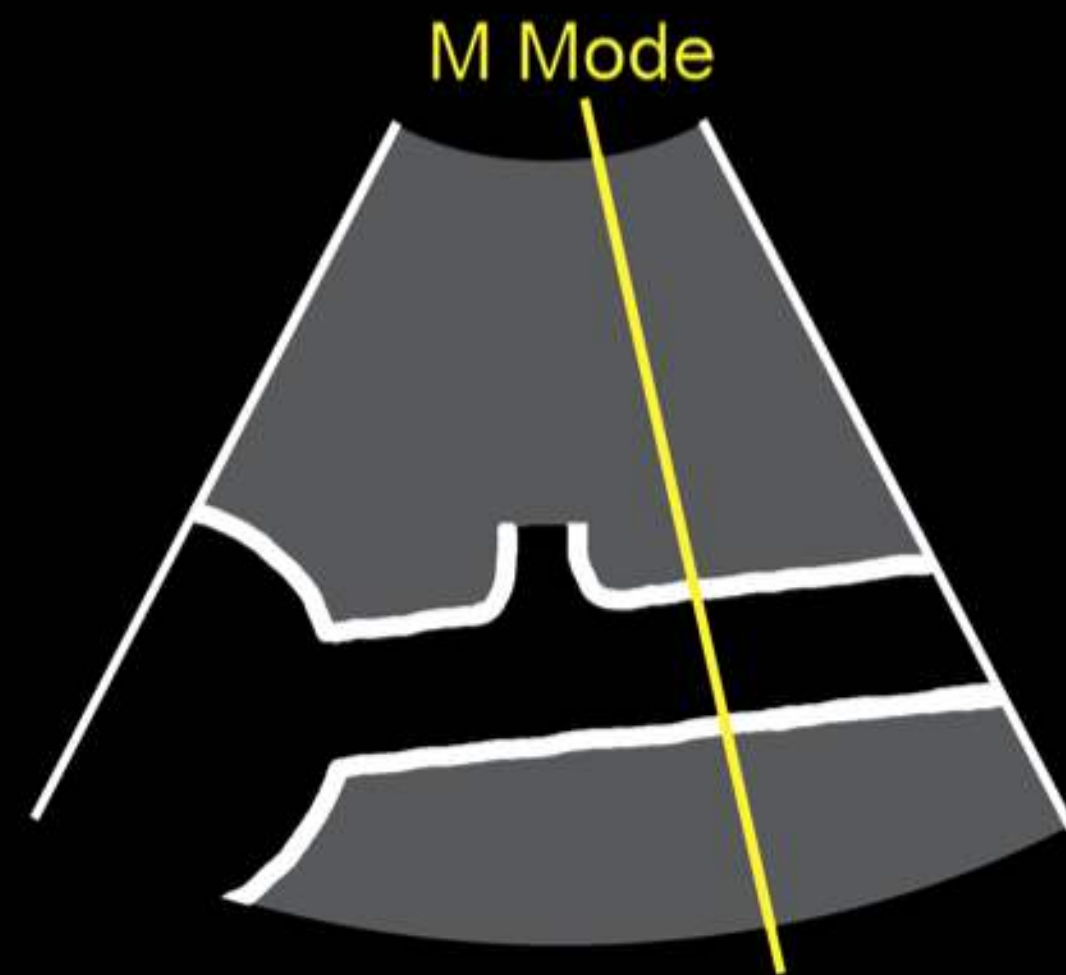
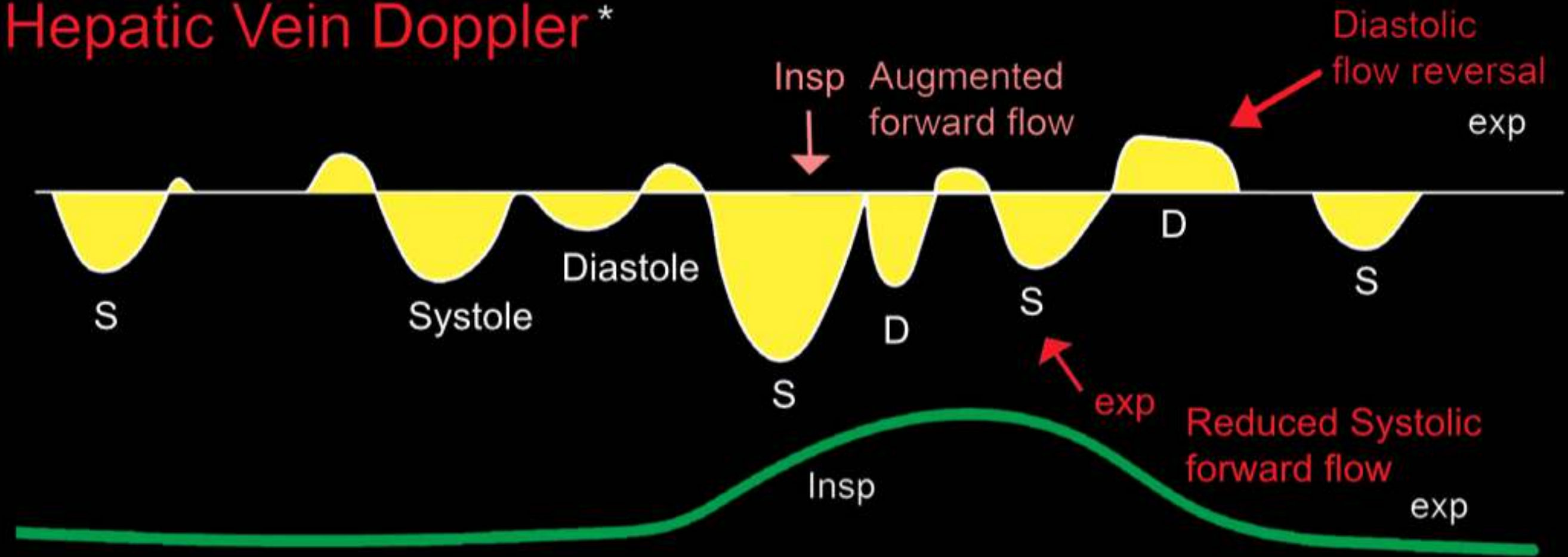


Cardiac Tamponade

Hepatic Vein Doppler / IVC



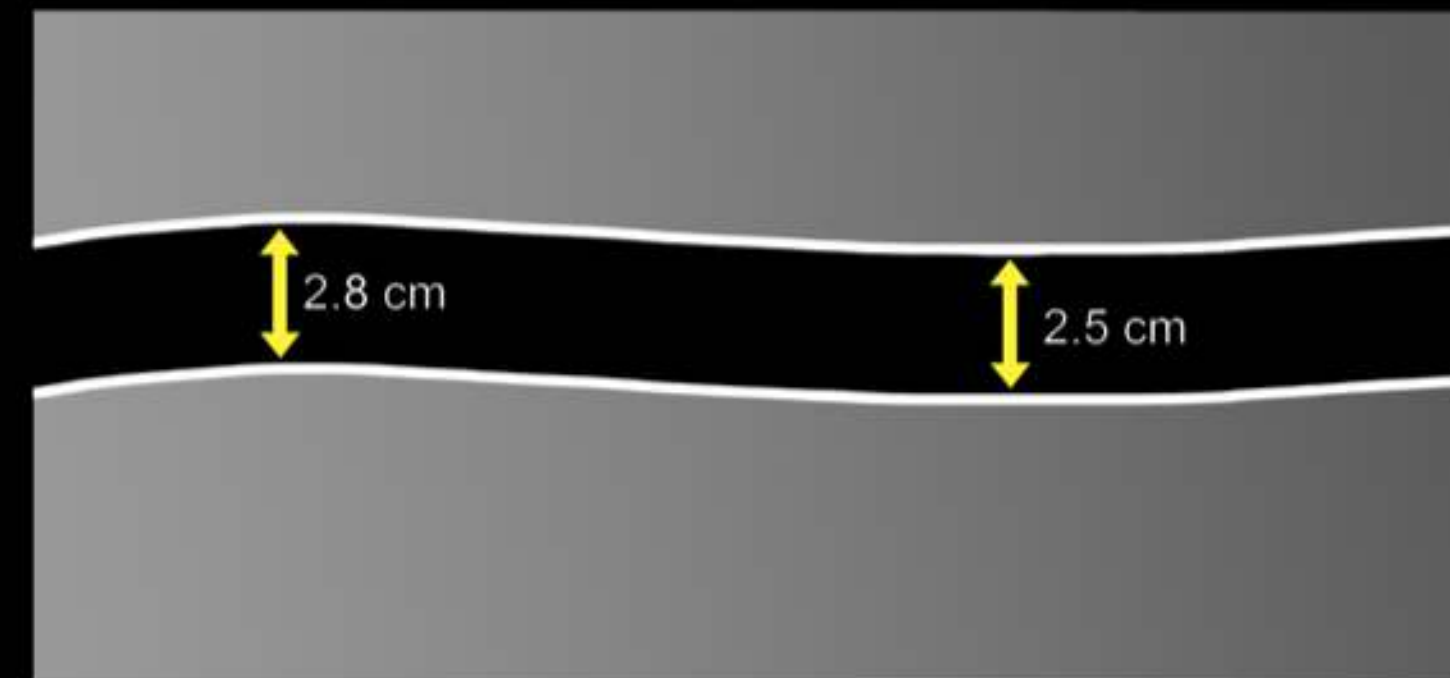
Hepatic Vein Doppler*



M Mode IVC*

Plethoric IVC
> 2.1 cm
< 50% Collapse

92-97% Sensitive
for tamonade



* Respiratory changes expected in non-intubated spontaneously breathing patients