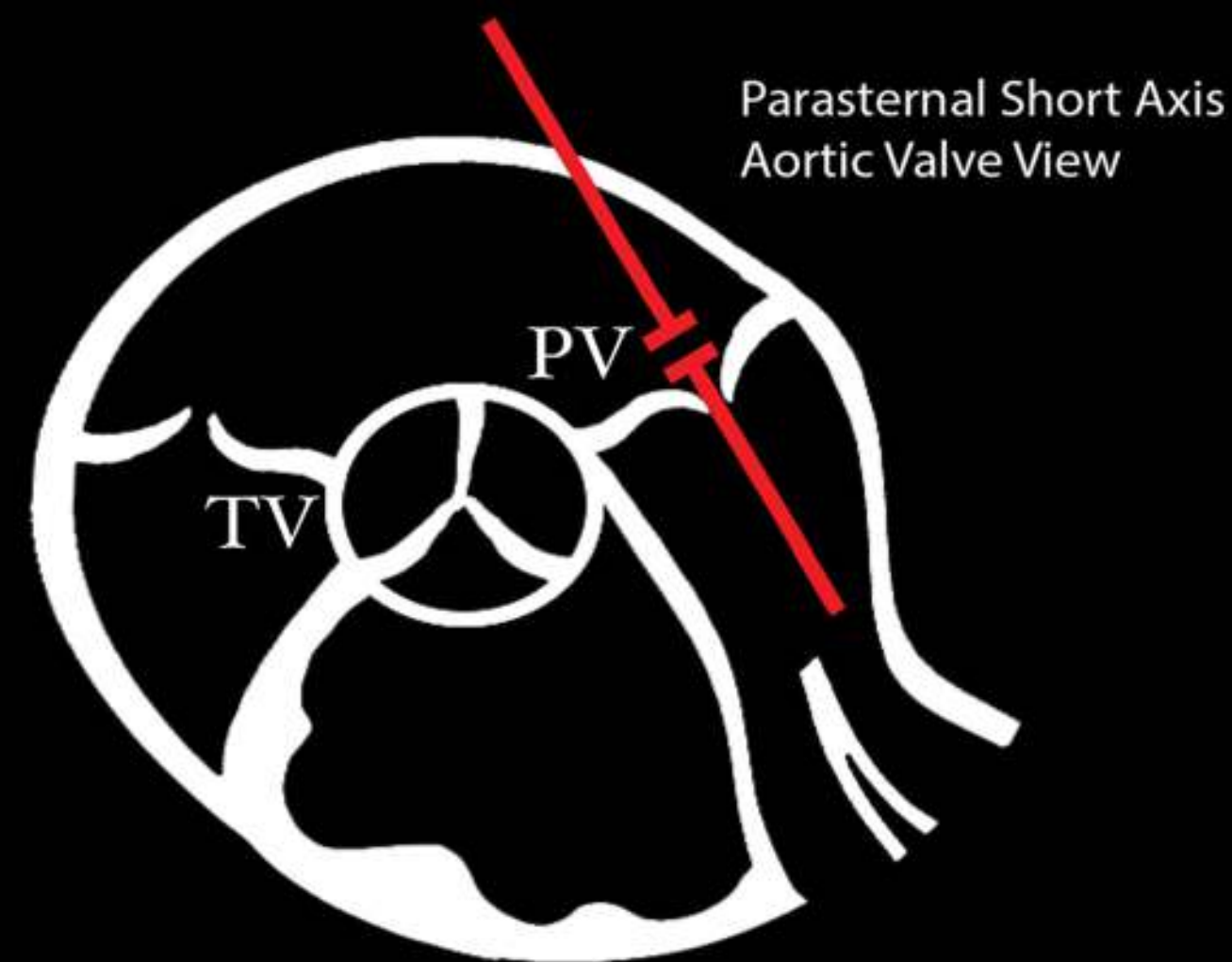
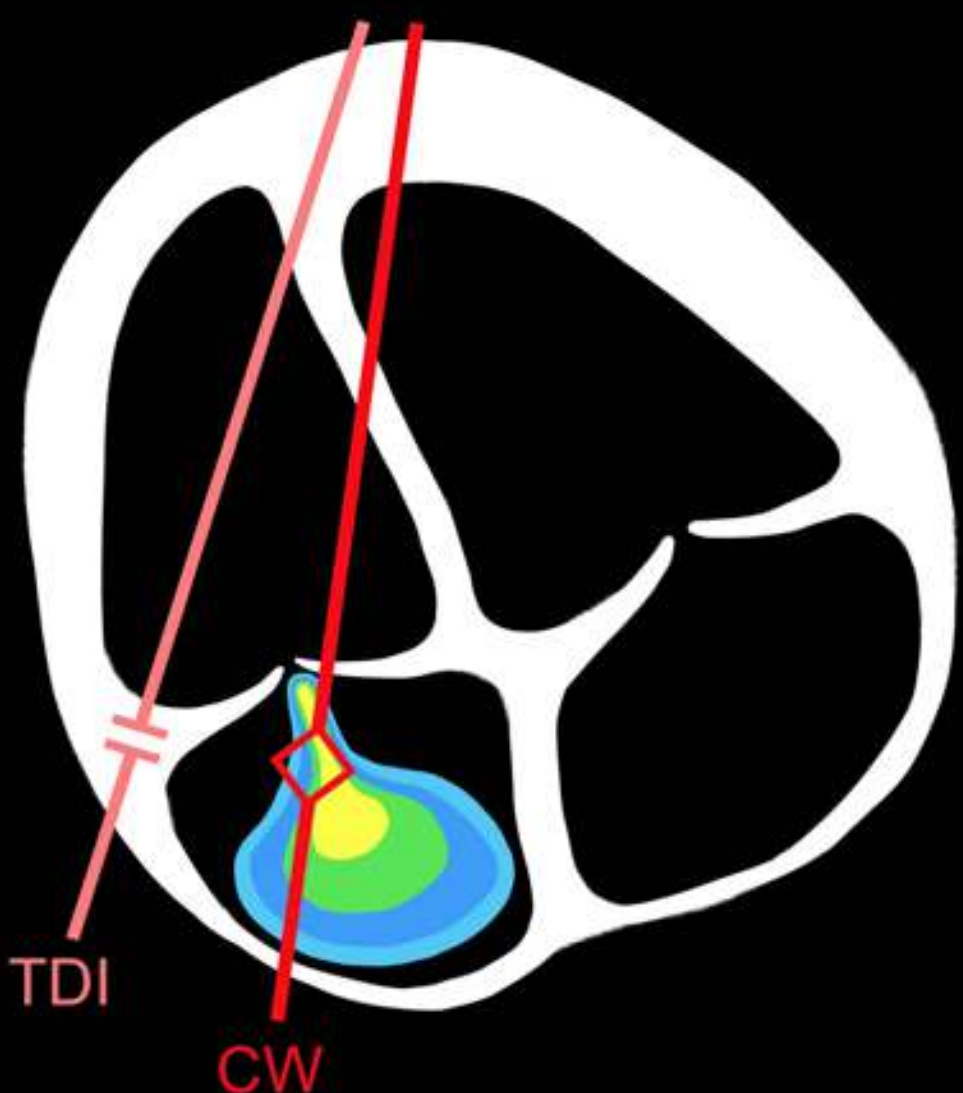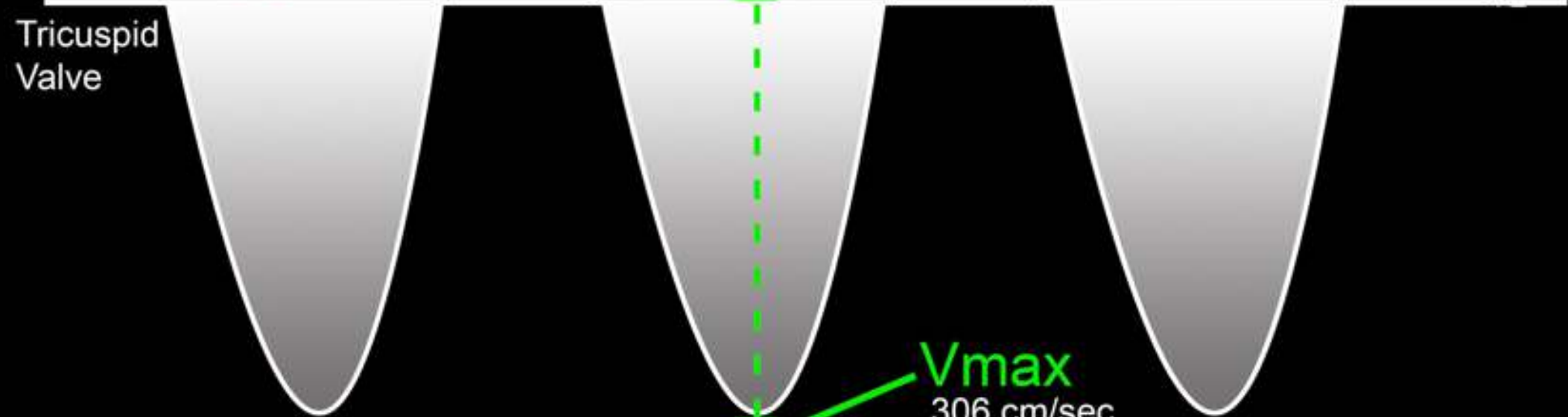


Right Heart Advanced



IVC Size	IVC Collapse	CVP (mmHg) *Estimated
< 2.1 cm	>50%	3 mmHg *
< 2.1 cm	<50%	8 mmHg *
> 2.1 cm	>50%	8 mmHg *
> 2.1 cm	<50%	15 mmHg *

CW Doppler

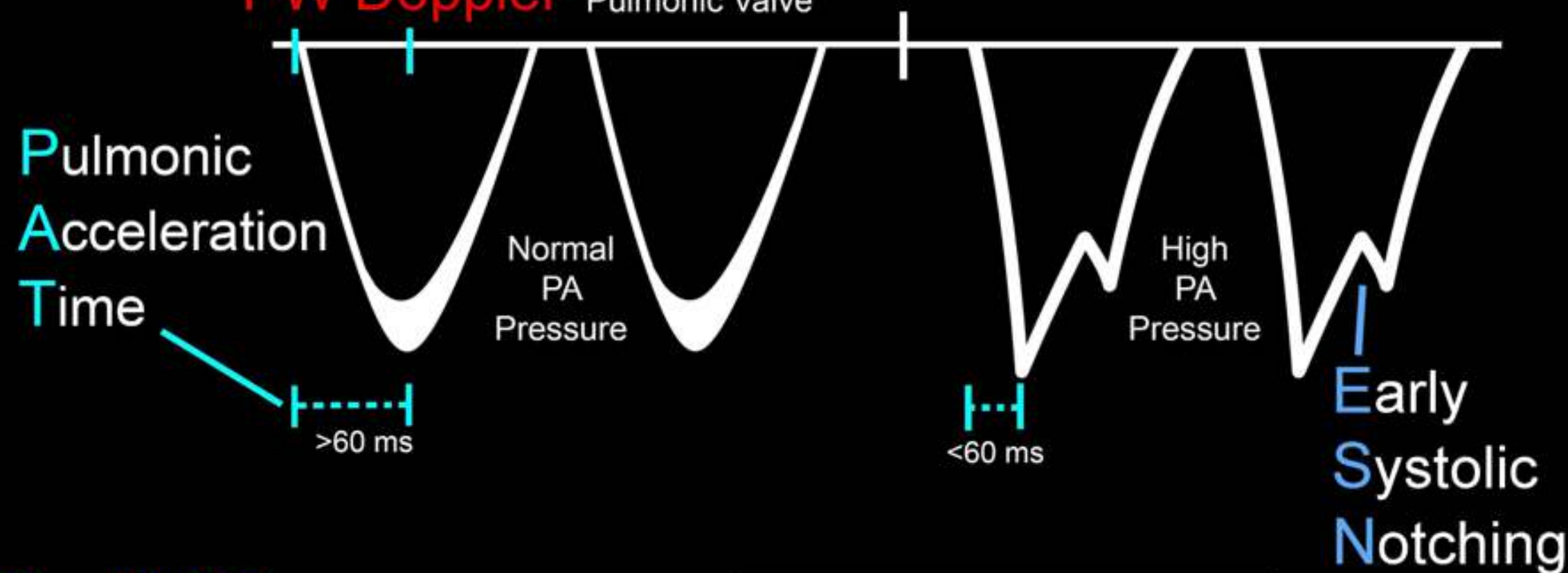


Vmax
306 cm/sec

PG = 37 mmHg

TR Jet PG + CVP = RVSP

PW Doppler



>60 ms

<60 ms

Early Systolic Notching

Tissue Doppler



s' = Vmax
8 cm/sec

RV Failure

s' < 9.5 cm/sec
ESN present
TAPSE < 17 mm

Acute RV Failure
60 / 60 Sign =

RVSP < 60 mmHg
and
PAT < 60 ms