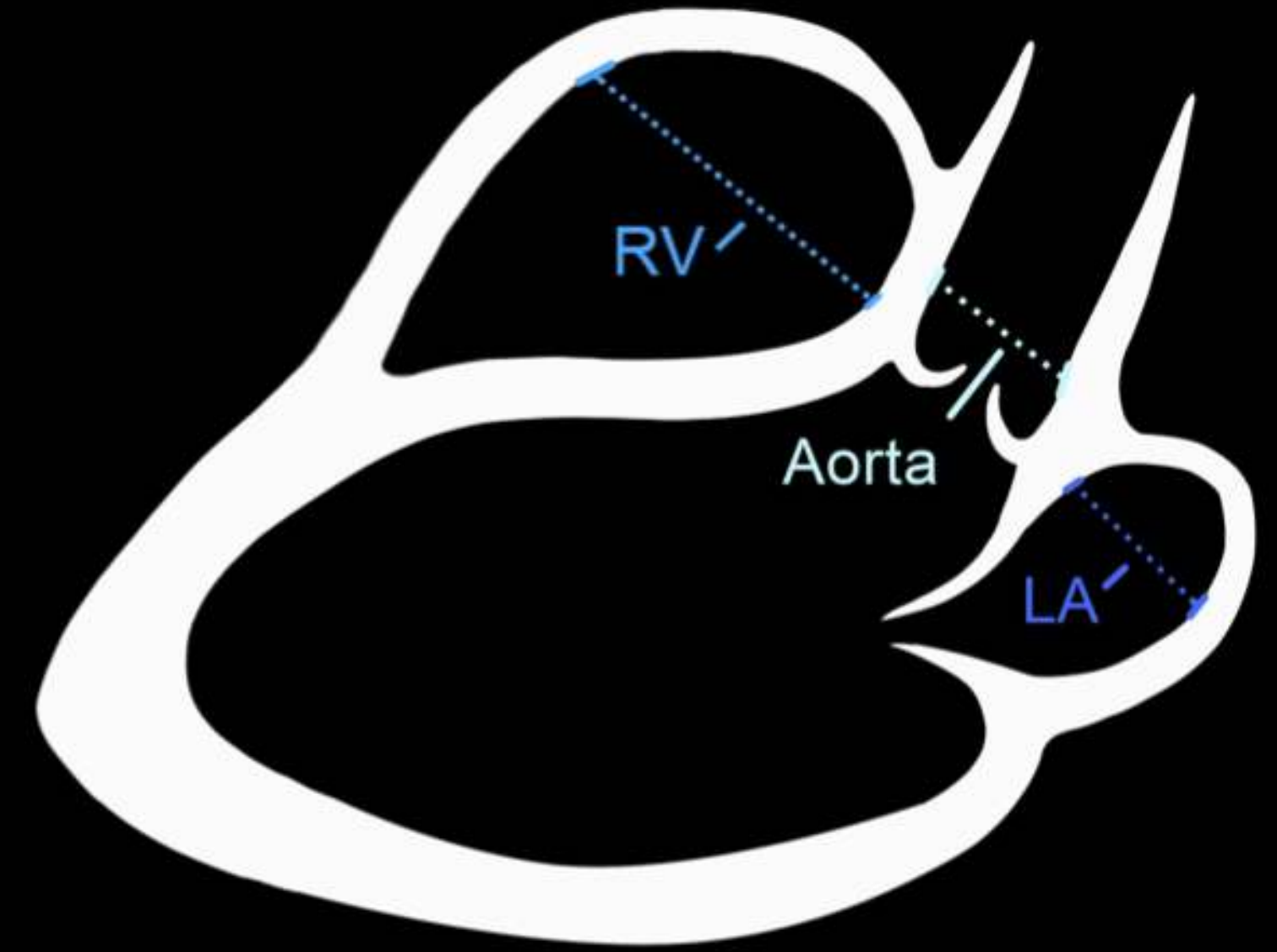
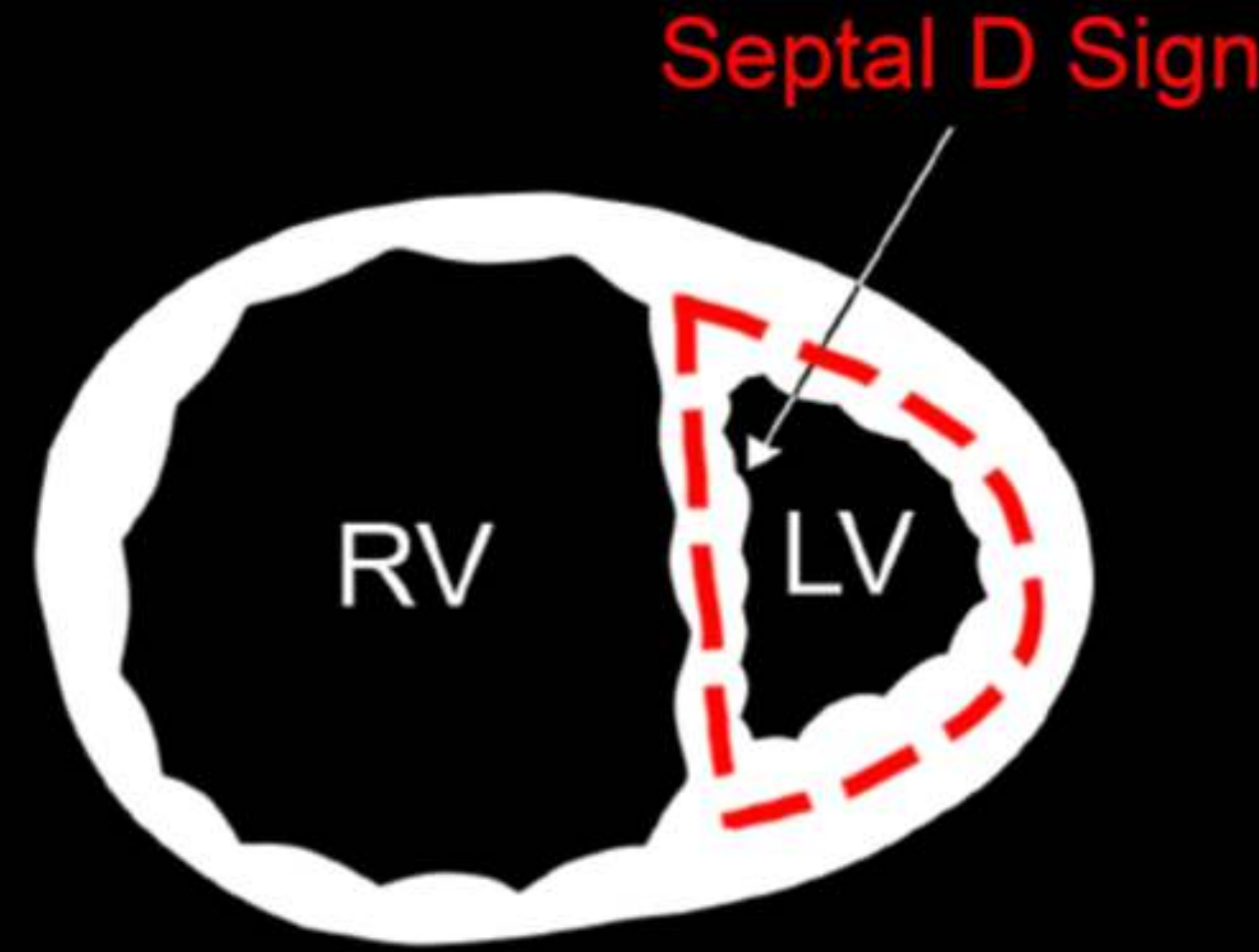
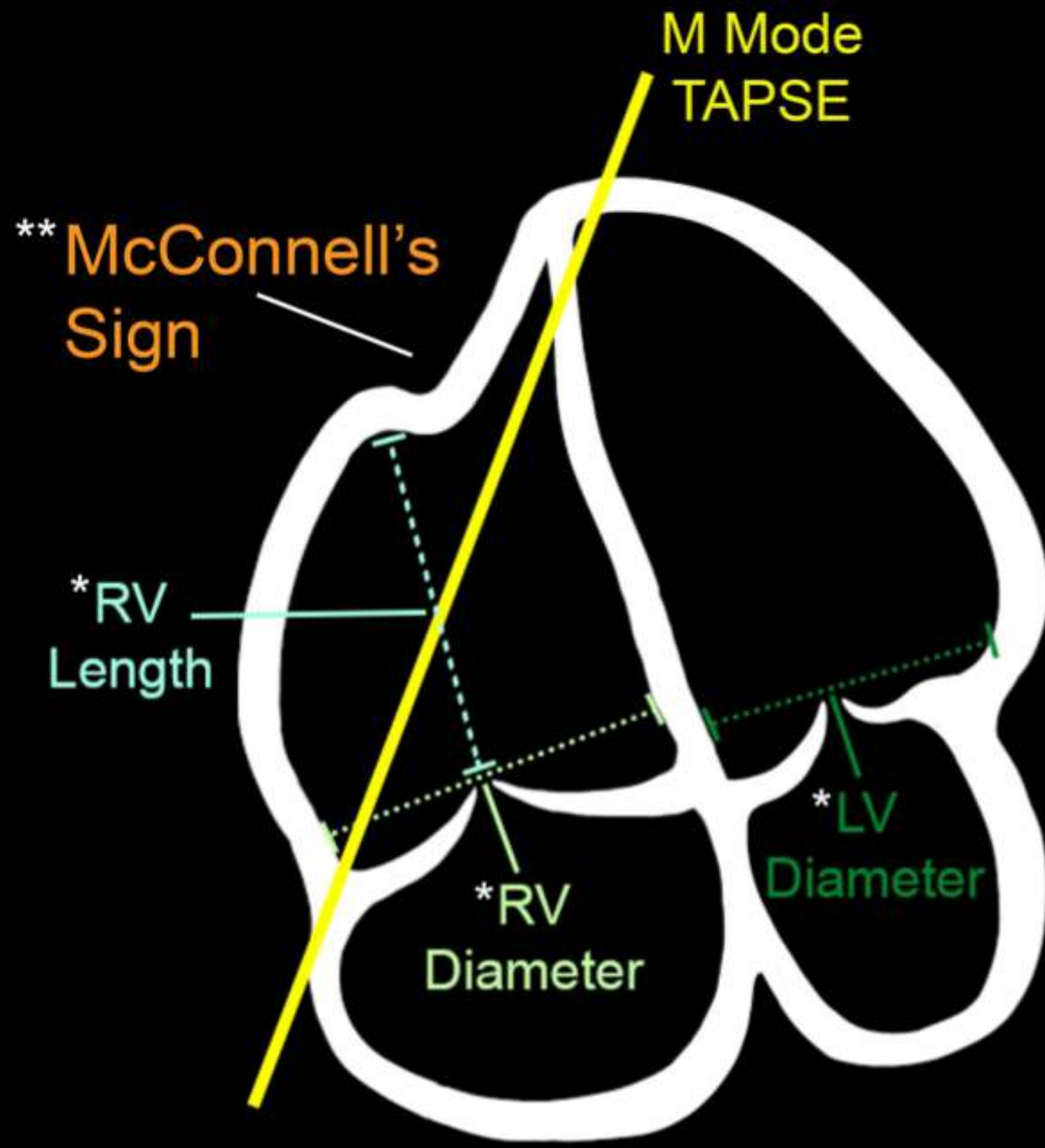



Right Heart Strain

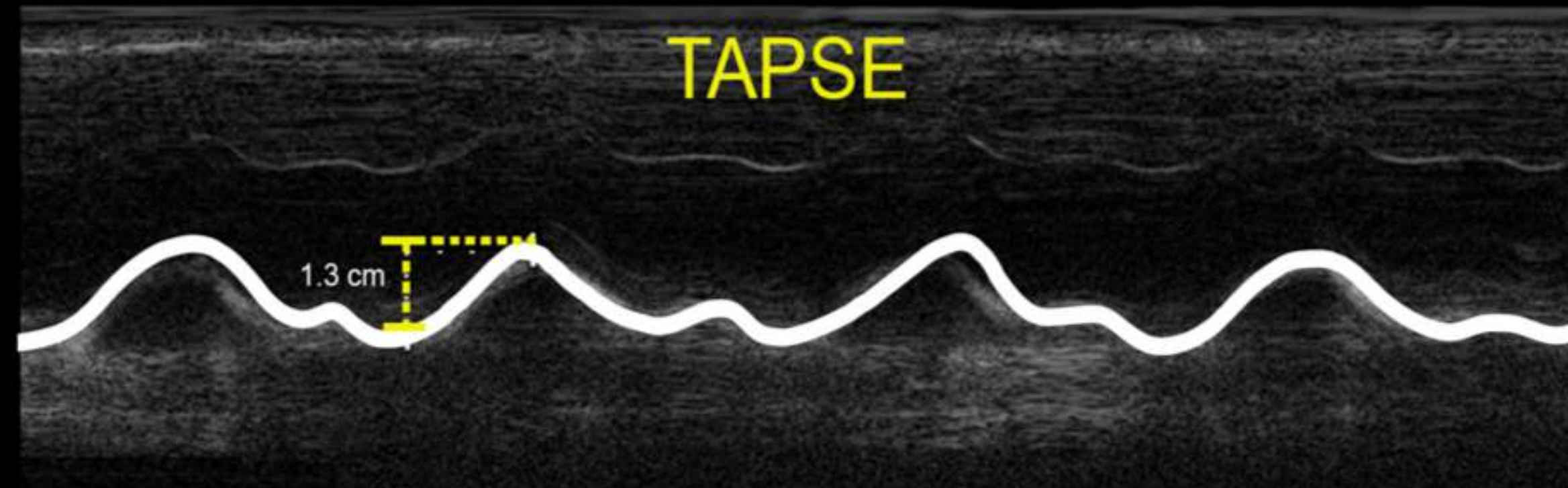


RV > 3.5 cm
RV > LA and/or Aorta

** - Systole
 * - Diastole

RV Dilation

- RV Diameter > 4.1 cm
- RV Length > 8.3 cm
- $\frac{\text{RV Diameter}}{\text{LV Diameter}} > 0.6$



RV Strain

- RV Dilation
- Septal D Sign
- McConnell's Sign
- TAPSE < 17 mm**